



Shobana Rajan, M.D. Staff Anesthesiologist,
Cleveland Clinic, Cleveland, Ohio

Shaheen Shaikh, M.D. Assistant Professor of Anesthesiology, University
of Massachusetts Medical center, Worcester, MA.

This quiz is being published on behalf of the Education Committee of the
SNACC.

Go to Q 1

1. 46 Y/M with H/O multiple AV malformations in the brain, currently coming for excision of an AV malformation. He has a BMI of 31, H/O obstructive sleep apnea and hypertension on medication. Neuroimaging shows an AV malformation in the mid brain pons region near the fourth ventricle. The following could be familial causes of AV malformations in the brain except,

- A. [Hereditary hemorrhagic telangiectasia](#)
- B. [Von-Hippel Lindau disease](#)
- C. [Marfan's syndrome](#)
- D. [Cerebral cavernous malformation\(ccm\) gene](#)



Go to Q 2

A. Hereditary hemorrhagic telangiectasia

Hereditary hemorrhagic telangiectasia (HHT) or Rendu-Osler-Weber syndrome, is a multisystemic vascular dysplasia. It is an autosomal dominant disorder of mucocutaneous

fragility and AVMs in various organs including the brain. There are at least five genes associated with HHT, but the two main subtypes of HHT (HHT1 and HHT2) are caused by loss-of-function mutations of ENG gene and the ALK-1 gene respectively. These two genes are implicated in transforming growth factor- β (TGF- β) signaling pathways which is involved in vascular remodelling and angiogenesis. Clinically, the consequences of these mutations are represented by the formation of cutaneous and/or mucous telangiectases and arterio-venous fistulas

Ref; Colotto M1 et al; Clin Ter. 2007 May-Jun;158(3):253-60.

[Hereditary hemorrhagic telangiectasia: the state of art].

[Try again](#)

Incorrect

B. Von-Hippel Lindau disease

Von Hippel-Lindau disease (VHL) is caused by a rare genetic mutation (approximate incidence 1 in 36 000) inherited as autosomal dominant with variable penetrance. It predisposes patients to benign and malignant capillary hemangioblastomas of the brain. Anesthetic management of patients with VHL depends on many factors including the presence of central nervous system tumors and the consequences of previous tumor resections. Careful preoperative assessment and proper planning is necessary.

[Try again](#)

Incorrect

C. Marfan's syndrome



Marfan syndrome (MFS) is a connective tissue disorder inherited in an autosomal dominant fashion and that is classically caused by mutations in the gene coding for fibrillin-1. The high mortality of untreated MFS results almost exclusively from aortic complications such as aortic dissection and rupture. It is not likely to cause AVMs in the brain.

Back to Q1

Go to Q2

D. Cerebral cavernous malformation (ccm) gene

Cerebral cavernous malformations (CCMs) are vascular malformations consisting of closely clustered enlarged capillary channels (caverns) with a single layer of endothelium without normal mature vessel wall elements or intervening brain parenchyma. Familial cerebral cavernous malformation (FCCM) is defined as the occurrence of CCMs in at least two family members and/or the presence of multiple CCMs and/or the presence of a disease-causing mutation in one of the three genes in which mutations are known to cause familial CCM. The diagnosis of FCCM can be confirmed by molecular genetic testing of the following three genes in which mutations are known to cause FCCM: KRIT1 (locus name CCM1), CCM2 (locus CCM2), and PDCD10 (locus CCM3).

[Try again](#)

Incorrect

2. The most common presenting feature of AV malformations in the brain is

- A. [Seizures](#)
- B. [Numbness](#)
- C. [Headaches](#)
- D. [Intracranial hemorrhage](#)

Go to Q3



A. Seizures

The second most common form of AVM presentation is symptomatic epilepsy (about 26%). Anatomic characteristics of AVM associated with epileptic presentation include size, cortical location of the nidus and location of the AVM in the middle cerebral artery territory.

Aki Laakso ; Arteriovenous Malformations: Epidemiology and Clinical Presentation
Neurosurgery Clinics of North America, 2012-01-01, Volume 23, Issue 1, Pages 1-6 C

[Try again](#)

Incorrect

B. Numbness

Due to location, some patient may experience numbness or other focal neurologic signs but this is not the most common presentation.

[Try again](#)

Incorrect

C. Headaches

Although not the most common presentation, a significant subset of patients may present with debilitating headaches that are not due to hemorrhage.

These headaches tend to be chronic and recurring in nature very similar to migraine. Some patients may have prominent visual and other migraine-like symptoms are associated with occipital AVM

Jason A. Ellis et al; Arteriovenous malformations and headache;
Journal of Clinical Neuroscience, 2016-01-01, Volume 23, Pages 38-43.

[Try again](#)

Incorrect

D. Intracranial hemorrhage



The most common presentation and source of morbidity from AVMs is spontaneous intra-cranial hemorrhage (ICH), which occurs in about one half of all patients with AVMs. Independent risk factors for hemorrhagic presentation include small size, deep venous drainage, infratentorial locations, associated aneurysms, hypertension, and high feeding artery pressure.

Ref: William L. Young et al, Cottrell and Young's textbook of neuroanesthesia, ch 15, page 264
Aki Laakso ; Arteriovenous Malformations: Epidemiology and Clinical Presentation R
Neurosurgery Clinics of North America, 2012-01-01, Volume 23, Issue 1, Pages 1-6 C

Back to Q2

Go to Q3

3. 64 y/o man with a PMH: HTN, DM, HPL presented with HA, gait abnormality, and blurred vision. Workup revealed a right cerebellar ICH and a right cerebellar AVM. The next step in management would be which of the following

- A. Steroids
- B. Antihypertensive management
- C. Nimodipine
- D. Hypervolemia



Go to Q4

A. Steroids

There is no evidence to support the routine use of corticosteroids in patients with intracranial hemorrhage. In fact, treatment with corticosteroids may be associated with an increased risk of adverse effects.

[Try again](#)

Incorrect

B. Antihypertensive management



Current approaches favor rapid lowering of moderately elevated blood pressures. Two pilot randomized clinical trials, INTERACT and ATACH, suggested that acutely lowering systolic blood pressure to below 140 mmHg is safe. INTERACT2 was a phase III clinical trial in which patients were randomized to two different blood pressure thresholds: a standard threshold of <180 mmHg and an intensive threshold of less than 140 mmHg. Patients in the intensive arm had modestly better outcomes with about 4 % fewer patients having death or severe disability (defined as a modified Rankin Scale score of 3–6).

1. Antihypertensive Treatment of Acute Cerebral Hemorrhage (ATACH) investigators. Antihypertensive treatment of acute cerebral hemorrhage. *Crit Care Med.* 2010;38:637–48.

2. Anderson CS, Huang Y, Wang JG, et al. Intensive blood pressure reduction in acute cerebral haemorrhage trial (INTERACT): a randomised pilot trial. *Lancet Neurol* 2008;7:391–9.

3. Anderson CS, Heeley E, Huang Y, et al. Rapid blood-pressure lowering in patients with acute intracerebral hemorrhage. *N Engl J Med.* 2013;368:2355–65.

Back to Q3

Go to Q4

C. Nimodipine

Nimodipine is used for vasospasm prevention and management in situations of subarachnoid hemorrhage or after intracranial aneurysm clipping. It does not have a role in the current situation of cerebellar bleed after an AV malformation.

[Try again](#)

Incorrect

D. Hypervolemia

Hypervolemia and hypertension are commonly used to ameliorate vasospasm after SAH and is not the correct answer in the above situation.

[Try again](#)

Incorrect

4. 39 y/o man with a history of seizures and headache comes for an elective resection of a cerebral AVM. The following would be neuro-protective strategies except

- A. Iatrogenic fluid restriction
- B. Avoidance of glucose containing fluids
- C. Prevention of Hyperthermia
- D. Relaxation of brain



Go to Q 5

A. Iatrogenic fluid restriction



Euvolemia is favored to maintain stable systemic and cerebral hemodynamics. In general isotonic fluids are preferred to prevent cerebral edema. Importantly fluid should not be withheld at the expense of a stable cardio-vascular status.

Cottrell and Young's textbook of neuroanesthesia;
ch 15, page 271

Back to Q4

Go to Q5

B. Avoidance of glucose containing fluids

The stress of surgery and the use of steroids may contribute to peri-operative hyperglycemia. There is considerable evidence that this hyperglycemia aggravates cerebral injury. Hence the most rational approach is to avoid glucose-containing fluids unless there is a specific indication for them.

[Try again](#)

Incorrect

C. Prevention of Hyperthermia

Hyperthermia must be avoided as it potentiates ischemic damage. Although there have been studies recommending hypothermia as being neuroprotective, hypothermia has other side-effects.

[Try again](#)

Incorrect

D. Relaxation of the brain

Interventions that reduce brain volume may help ameliorate retractor-induced ischemia. Adequate brain relaxation involves

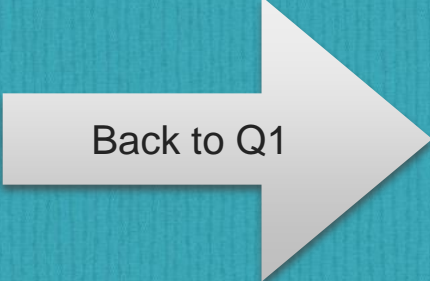
1. Optimal head position to promote intracranial venous drainage.
2. Avoidance of excessive neck flexion
3. Modest hypocapnia
4. Osmotic diuretics
5. Removal of cerebrospinal fluid.

[Try again](#)

Incorrect

5. A 40 year old male presents for excision of an AVM in the cerebellar hemisphere. He has a history significant for Von-Hippel Lindau disease. His blood pressure during previous visits seem unusually high. During induction of anesthesia and laryngoscopy, he developed hypertensive crisis. This could have been prevented by

- A. CT scan of abdomen
- B. Given metoprolol instead of esmolol
- C. Using Etomidate instead of propofol
- D. Instillation of laryngotracheal lidocaine before intubation



Back to Q1

A. CT scan of abdomen



Von Lindau Disease (VHLD) is a rare autosomal dominant disease with incomplete penetrance and variable expression. The characteristic lesions are capillary hemangioblastomas particularly of the central nervous system. It may be associated with bilateral pheochromocytoma in some patients (when associated with multiple endocrine neoplasia type 2) and if unrecognized can cause hypertensive crises under anesthesia. Hence CT scan of the abdomen could have helped detection of pheochromocytoma and adequate preparation with preoperative alpha and beta blockers could have prevented this.

Gurunathan, U, Korula G: Unsuspected Pheochromocytoma: Von Hippel-Lindau Disease. Journal of Neurosurgical Anesthesiology: Volume 16(1), January 2004, pp 26-28

Back to Q5

Back to Q1

B. Given metoprolol instead of esmolol

Neurologic symptoms in a patient with VHL with hemangioblastomas of the brain include those of raised intracranial pressure (ICP). Associated pheochromocytoma (usually bilateral) renders them prone to hemodynamic fluctuations, which can be hazardous because it can lead to further increase in ICP and intratumoral bleed. Therefore, adequate preparation with alpha and beta blockers is essential for maintaining hemodynamic stability- giving only beta blockers can leave the alpha receptors unopposed

[Try again](#)

Sanjay Goel et al; Anesthesia for Emergency Craniotomy in a Patient with von Hippel Lindau Disease With Pheochromocytoma. Journal of Neurosurgical Anesthesiology; Volume 17(3), July 2005, pp 173-174

Incorrect

C. Using Etomidate instead of propofol

Etomidate is commonly used in situations where the hypotension caused by propofol needs to be avoided. However, it would not have been useful in this situation.

[Try again](#)

Incorrect

D. Instillation of laryngotracheal lidocaine before intubation

Although this could possibly help in attenuating the hypertensive response to intubation- in a situation like the above, it may still not be adequate.

[Try again](#)

Incorrect